



The α -mangostin effect on the quantity of TGF- β 1 titer relate to the mandibular bone volume of *Rattus novergicus* in the periodontitis model

[Efecto de α -mangostin sobre los títulos de TGF- β 1 que se relacionan con el volumen óseo mandibular de *Rattus novergicus* en el modelo de periodontitis]

Citra Lestari^{1,2*}, Eryati Darwin¹, Deddi Prima Putra³, Netti Suharti⁴

¹Department of Histology, Faculty of Medicine, Universitas Andalas Padang, Sumatera Barat, Indonesia.

²Department of Periodontology, Faculty of Dentistry, Universitas Baiturrahmah Padang, Sumatera Barat, Indonesia.

³Faculty of Pharmacy, Universitas Andalas Padang, Sumatera Barat, Indonesia.

⁴Department of Microbiology, Faculty of Medicine, Universitas Andalas Padang, Sumatera Barat, Indonesia.

*E-mail: citralestari@fkg.unbrah.ac.id

Abstract

Context: Periodontitis causes pocket formation, gingival recession, and destruction of periodontal ligaments and alveolar bone. Periodontitis disturbs the attachment of periodontal ligaments to the maxillary and mandibular bones. The α -mangostin has shown role-playing in the bone remodeling process.

Aims: To evaluate the potential of α -mangostin induce the TGF β 1 titer associated with the increased mandibular bone volume on the alveolar bone remodeling of periodontitis of *Rattus novergicus*.

Methods: The α -mangostin used to the single administration dosage on the rat periodontitis model on the 7 and 14 days. TGF- β 1 titer tested by enzyme-linked immunosorbent assay, while the X-Ray Micro-CT/Micro Computed Tomography examined the volume's development of the mandibular bone.

Results: At the 7 days, 0.5 and 1% of α -mangostin had a better effect to increase the bone volume, and TGF- β 1 titer has linearity of bone development at concentrations of 0.5 to 2%. At 14 days, 1 and 2% of α -mangostin exhibited a better effect on inducing an increase in mandibular bone volume and TGF- β 1 titer. The linearity of both occurs at concentrations of 0.5 to 1%. The Micro-CT of the mandibular bone showed callus or new bone formation at the edge of each treatment group's lesion as an indicator of bone remodeling.

Conclusions: α -Mangostin induced an increase in the TGF- β 1 titer, which was in line with the rise in the volume of the mandibular bone of *Rattus novergicus*.

Keywords: bone volume; mandibular; α -mangostin; periodontitis; TGF- β 1.

Resumen

Contexto: La periodontitis causa la formación de bolsas, recesión gingival y destrucción de los ligamentos periodontales y el hueso alveolar. La periodontitis altera la unión de los ligamentos periodontales a los huesos maxilar y mandibular. Se ha demostrado que α -mangostin desempeña un papel en el proceso de remodelación ósea.

Objetivos: Evaluar el potencial de α -mangostin para inducir el título de TGF β 1 asociado con el aumento del volumen óseo mandibular en la remodelación del hueso alveolar de la periodontitis de *Rattus novergicus*.

Métodos: α -Mangostina se utilizó a la dosis de administración única en el modelo de periodontitis de rata a los 7 y 14 días. El título de TGF- β 1 se evaluó mediante un ensayo inmunoabsorbente ligado a enzimas, mientras que el Micro-CT/Micro Tomografía de rayos X examinó el desarrollo del volumen del hueso mandibular.

Resultados: A los 7 días, 0,5 y 1% de α -mangostin tuvo un mejor efecto para aumentar el volumen óseo, y el título de TGF- β 1 tiene linealidad de desarrollo óseo a concentraciones de 0.5 a 2%. A los 14 días, 1 y 2% de α -mangostin exhibió un mejor efecto en la inducción de un aumento en el volumen del hueso mandibular y el título de TGF- β 1. La linealidad de ambos se produce a concentraciones de 0,5 a 1%. La Micro-TC del hueso mandibular mostró callos o formación de hueso nuevo en el borde de la lesión de cada grupo de tratamiento como indicador de remodelado óseo.

Conclusiones: α -Mangostin indujo un aumento del título de TGF- β 1, que estuvo en línea con el aumento del volumen del hueso mandibular de *Rattus novergicus*.

Palabras Clave: mandibular α -mangostin; periodontitis; TGF- β ; volumen óseo.

ARTICLE INFO

Received: January 9, 2021.

Received in revised form: March 30, 2021.

Accepted: April 4, 2021.

Available Online: April 14, 2021.



INTRODUCTION

Periodontitis is a disease caused by an increase in plaque formed as a result of bacterial metabolism. This infection is characterized by damage to the periodontal tissues, including the periodontal ligament and alveolar bone. (Könönen et al., 2019) The level of alveolar bone loss depends on the host response stimulated by the bacterial infection (Hienz et al., 2015). The impact of periodontitis can cause pocket formation and gingival recession, and tooth loss (Schätzle, 2005). In periodontitis, the bacteria gradually damage the mandibular bone and periodontal ligament, thereby disrupting the teeth (Hajishengallis, 2015). The main impact on mandibular bone destruction is to increase the tooth-supporting tissue's destructiveness and decrease the function of the teeth and gingiva. Chronic periodontitis can lead to mandible bone loss (Wactawski-Wende et al., 1996).

The therapy aims to stabilize, reorganize the gingival tissue, periodontal fibers, and alveolar bone (Yang et al., 2020). The treatment of tooth mobility in periodontal disease is determined by the degree of damage to the bone supports. Treatment of mobility due to periodontal space widening can be accomplished with occlusal adjustments and periodontal therapy (Soares et al., 2011). In treating teeth with gingival inflammation and high mobility, and loss of bone tissue, a combination of periodontal treatment and occlusal adjustments and dental restraint is performed. The mandibular bone damage is complicated to heal to affect and interfere with periodontitis treatment (Jati et al., 2016). Bone remodeling is a strategic one to restore the mandibular bone function to support the alveolar bone and periodontal ligament so that infection healing is in line with bone care (Jiang et al., 2016).

The use of antiresorptive drugs reduces bone remodeling in mandibular bone therapy (Song, 2019). Besides, the use of antiangiogenic drugs such as Vascular endothelial growth factor (VEGF) antagonists has shown promising results. However, these treatments are not curative and can have significant side effects (Hu and Olsen, 2016). The

use of natural ingredients is a focus in the herbal world for the bone remodeling process. Mangosteen bark extract (*Garcinia mangostana*) combined with demineralized freeze-dried bovine bone xenograft (DFBBX) can reduce inflammation, reduce osteoclasts, decrease alveolar bone resorption, and also increase BMP2 expression and alveolar bone regeneration (Kresnoadi et al., 2017).

The α -mangostin reported as an anti-inflammatory in adipose tissue in metabolic disorders of aging. Besides, α -mangostin can bind the ligand of nuclear factor- κ B receptor activators, which induces osteoclast formation and bone resorption (Hong et al., 2018). Transforming growth factor-beta (TGF-beta) is reported to be involved in bone remodeling, including mandibular bone because TGF-beta plays a role in stimulating matrix protein synthesis. Furthermore, TGF-beta plays a role in embryonal development, cell differentiation, hormone secretion, and immune function. TGF- β 1 is a regulatory immune cytokine that regulates immune cell proliferation, skeletal system formation (osteoimmunology), and skeletal tissue development and maintenance (Kasagi and Chen, 2013).

TGF- β 1 significantly affects the periodontal tissue response regulation and other inflammatory mediators involved in periodontal tissue repair. (Gürkan et al., 2006) The results of this study clarify the role of TGF- β 1 as a regulatory immune cytokine that regulates the development of the mandibular bone volume of *Rattus novergicus* in a periodontitis model with alveolar bone.

MATERIAL AND METHODS

Ethical procedures

The general research was approved of ethical clearance by Medical Faculty, Universitas Andalas, Padang Sumatera Barat, Indonesia, 569/KEP/FK/2018. Meanwhile, the sub research in the periodontitis model used to the animal model of ethical clearance was approved by Veterinary Faculty, Universitas Syiah Kuala, Darussalam, Banda Aceh, Indonesia No. 94/KEPH/VII/2020. A total of 36

rats were used in four groups that were influenced by α -mangostin. *Rattus novergicus*, as a model rat in this study, had a 10-week age and a bodyweight of 200 g. Before treatment, the rats were acclimatized for seven days in a conducive environment (temperature, water, food, light-dark cycle, and noise). The treatment of experimental animals in this study used the ARRIVE (Animals in Research: Reporting *In Vivo* Experiments) guidelines released by the National Center for the Replacement, Refinement, and Reduction of Animals in Research (NC3Rs) (Kilkenny et al., 2010; Nam et al., 2018).

Plant material

The plant as an assay material was obtained from Sumatera Barat Province, Indonesia. *Garcinia mangostana* L. was purified α -mangostin from Batusangkar, Kubang Landau (-0.4555771, 100.6409525), certificate of analysis No: 11/Rc-Fp/2017 by Andalas Sitawa Fitolab Andalas University, Padang, Sumatera Barat, Indonesia (GPS Coordinate, -0.9476875, 100.4529375), Product codes RC08402. The assay materials were collected by the writer Deddi Prima Putra from the Biota Sumatera Laboratory, Universitas Andalas, Padang, Sumatera Barat, Indonesia.

The isolation of α -mangostin refers to Mahato et al. (2019). The α -mangostin was isolated from pericarp of mangosteen rind. The purification process begins in two stages, namely extraction and fractionation. In the extraction process, the simplicity of the pericarp dry powder of the mangosteen rind is macerated with methanol as a solvent. Then the methanol extract was fractionated liquid with dichloromethane and water as a solvent. Then the dichloromethane fraction was collected. Furthermore, the fractionation process was carried out using the normal phase column chromatography method, then the silica gel stationary and mobile phases. This process uses a binary gradient method with a variation ratio of the mixture of n-hexane-dichloromethane. The subfraction obtained was monitored by thin-layer chromatography, and the subfraction containing α -mangostin was recrystallized using ethyl acetate-hexane as a solvent. Furthermore, α -mangostin was examined for purity by UV-Vis spectrum of High-

Performance Liquid Chromatography (HPLC). Then the spectroscopic data were taken (Fig. 1).

Periodontitis model

In this study, hyaluronic acid (Global Xtra, DermaFill Globa, Parid, France) was used as a positive control group at a dose of 25 mg/mL (Chang et al., 2016). While the concentration of α -mangostin was 200 mg/kg BW (Ng'uni et al., 2018). According to preliminary research, α -mangostin has an excellent ability to induce osteoblasts and osteoclasts at concentrations of 2.5% and 5%. These concentrations were used as a reference for their use in periodontitis modeling by reducing the dosage below 2.5%, namely 2%, 1%, and 0.5%, which were adopted from the study.

This study used time variables (7 days and 14 days) and α -mangostin concentrations (0.5, 1 and 2%) (Ghasemzadeh et al., 2018). A total of 36 *Rattus novergicus* were used as a model for periodontitis. The treatment started with anesthesia with xylazine (0.05 mL/100 g body weight) intramuscular (im.) on the rat's left thigh. Furthermore, \pm 5 min later, the rats were injected with ketamine HCl 0.1 mL/100 g body weight to cause a sedative effect. Then an incision was made using a scalpel knife No.15 with the opening of the full-thickness flap. The flap opened through the masseter and periosteum muscles until it reached the alveolar bone in the molar (M1) root area and molar (M2) in the left mandible. The alveolar bone was removed using a low-speed contra-angle with an inverted bur while rinsed with a saline solution of 0.9%.

The inflammation characterizes periodontitis, histological examination of blood polymorphonuclear cells taken from the periodontal tissue pocket showed positive signs of inflammation. Besides, the presence of osteoblasts and osteoclasts was presented (Kantarci et al., 2020). The exposed M1 and M2 roots were cleaned with a 0.9% saline solution of the periodontal ligament and cementum in the next stage. The α -mangostin hydrogel was placed on the damaged bone area until it was covered by all areas (\pm 6 μ L). It was assumed the acute treatment, and it also singles administration

application. Then the masseter muscle and skin were repositioned and sutured with absorbable surgery. The rats were then given buprenorphine HCl (0.01 mg/kg body weight, subcutaneous injection). The end period on the seventh day and the fourteenth day. The mice were euthanized, then the mandible was taken and fixed in 10% formalin solution for 48 h.

Assay of quantity TGF- β 1 titer

The evaluation of the TGF- β 1 titer used the method of ELISA (enzyme-linked immunosorbent assay). It was adopted by Burhan et al. (2018). The rat blood serum was collected from the plexus orbitalis. The assessment of TGF- β 1 titer using the TGF- β 1 Elisa kit (Biolegend Max®, San Diego, CA, USA). A total of 10 μ L of serum was added to the microtube. Furthermore, added 20 μ L of the acidifying solution, homogenized, and incubated for 10 min at room temperature. Then added 5 μ L of neutralization solution, homogenized. Then the serum was diluted according to the concentration (200 times dilution). Then filled each tube with a 199 μ L diluent sample and added 1 μ L serum.

The assay procedure begins by creating a standard curve, with concentrations of 7.8, 15.6, 31.3, 62.5, 125, 250, 500 μ g/mL and assay buffer as standard zero (0 μ g/mL). Then 50 μ L of assay buffer was added to each well, which would be filled with standard dilution or samples. The plates were closed with a sealer and incubated for 2 h at room temperature above the plug at 200 \times g. Then washed four times with 1 \times wash buffer. Then 100 μ L of TGF- β 1 detection antibody solution was added to each well, closed and incubated at room temperature for one hour while vortexed at 200 \times g, then washed four times with 1 \times wash buffer. Then 100 μ L of Avidin-HRP solution was added to each well, then closed and incubated at room temperature for 30 min. Then washed five times with 1 \times wash buffer. Then 100 μ L of substrate solution was added to each well and incubated for 10 min in a dark room. Well, which contained TGF- β 1 turns blue. The reaction stopped with a 100 μ L stop solution, so the color turned yellow. Then it is read at 450 nm in 30 min.

Mandibular bone volume measurement

Micro-morphometric measurements of bone parameters were carried out using Bruker SkyScan 1173 micro-tomography (X-Ray Micro-CT/Micro Computed Tomography). Scanning was performed with 75 kV X-Ray energy parameters, 100 μ A source current with 500 exposure time, image pixel size 12.114213 μ m, and rotation step of 0.200° (du Plessis et al., 2017).

The left mandible, fixed with 10% buffered formalin solution for 48 h, was scanned by micro-CT. The results of the scanning image were oriented in the transverse plane (margin-apical direction), sagittal plane (mesial-distal direction), and frontal plane (buccal-lingual direction). All regions were observed in the region of interest (ROI). The result of the projection image becomes CT tomography (reconstructed Micro-CT images). The assessment was carried out with reconstructed micro-CT images at the grey value level, namely 0 (black) - 255 (white). Then given a false-color limit: 0-9 (black-voids); 10-36 (purple-soft tissue and cancellous bone color); 37-100 (orange color-new tissue); 101-144 (bone-green color); 145-255 (blue to white-bone color compact and teeth). The bone volume fraction was measured as the percentage of bone volume filled in the region of interest using the BV/TV formula. Examinations were carried out in the seven-day and 14-day groups.

Statistical analysis

Data on the development of mandibular bone volume and TGF- β 1 expression between time and α -mangostin concentration were analyzed by Kruskal-Wallis Test with the Spearman correlation (IBM SPSS Statistics 20, International Business Machine Corporation, CA, USA). Meanwhile, the relationship between α -mangostin concentration and increased bone volume with TGF- β 1 titers was analyzed by One Way ANOVA with significant limits ($p < 0.05$) and marginal correlation ($r = 1$).

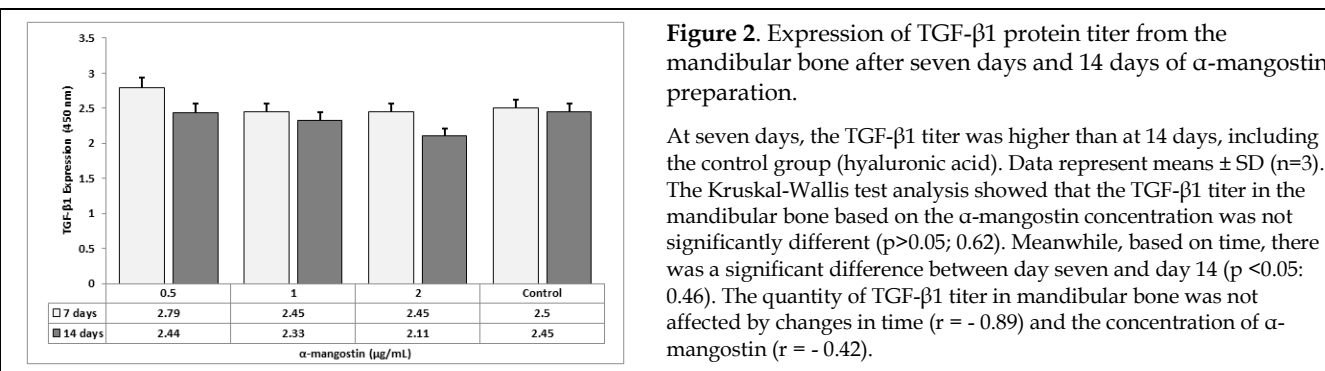
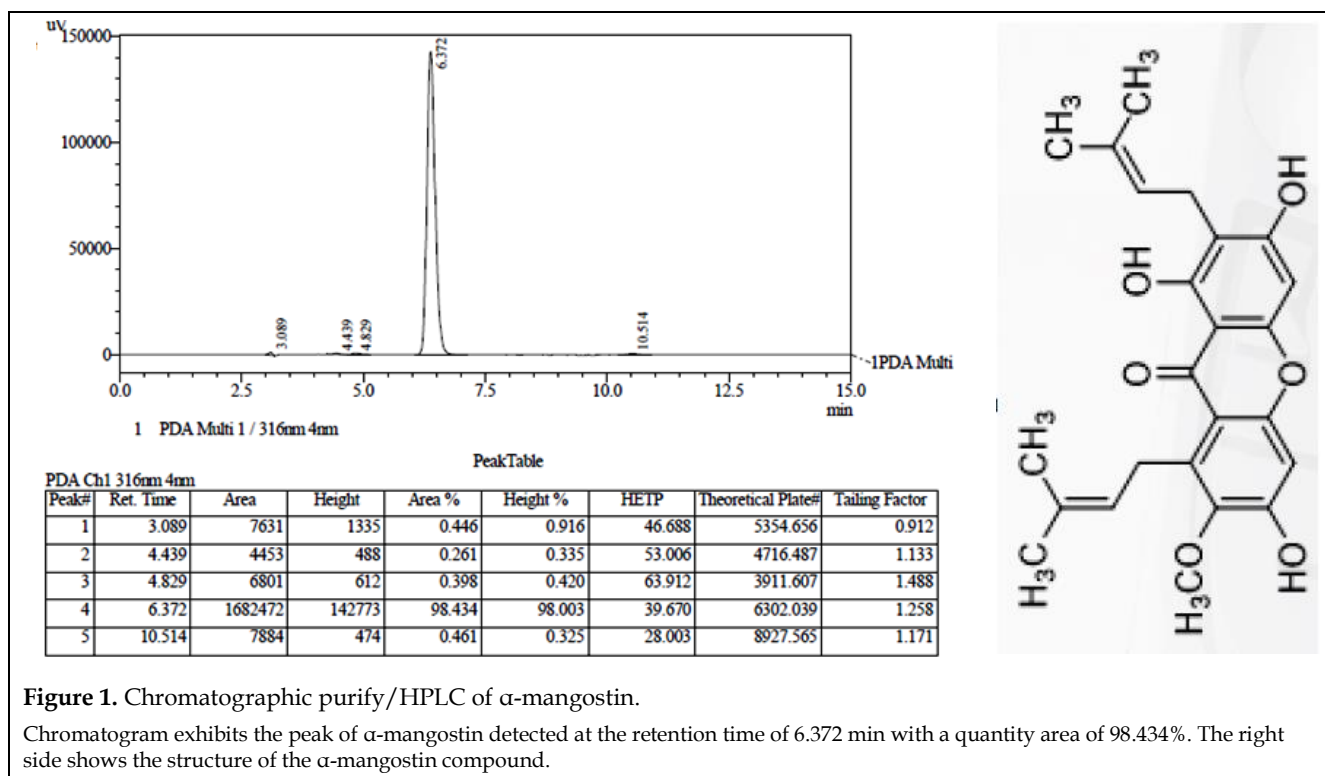
RESULTS

Fig. 1 shows the strength of the α -mangostin compound purified from the pericarp of mango-

steen peel. The α -mangostin quantity (98.4%) was able to respond well to the increase in TGF- β 1 titer (Fig. 2) and bone volume (Fig. 3) in the mandibular bone. Fig. 2 shows that at seven days, α -mangostin showed a good effect on inducing TGF- β 1, especially at a concentration of 0.5%. Meanwhile, at concentrations of 1 and 2%, they have the same ability to generate TGF- β 1. Fig. 3 shows that at seven days, α -mangostin exhibited a good effect on increasing bone volume, especially at a concentration of 1%. Meanwhile, at 14 days, 2% of α -mangostin revealed a better result. Fig. 4 shows that at seven days, the α -mangostin of 0.5 and 2%

displayed linearity in mandibular bone development. At the 14 days, mandibular bone development's linearity occurred at 0.5 and 1% of α -mangostin. These changes take into account that time affects the quantity of TGF- β 1 titer, accompanied by increased bone volume.

Fig. 5 shows a Micro-CT image that indicates the formation of a new callus or bone at the edges of each treatment group's lesion. The α -mangostin and hyaluronic acid (positive control) exhibited a different effect on the bone added volume in 7 and 14 days (Table 1).



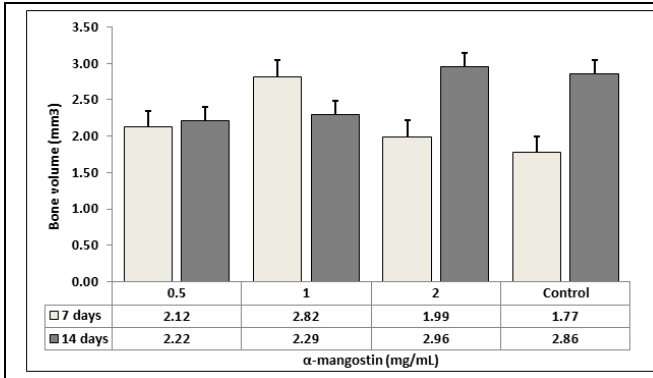


Figure 3. Changes in bone volume after seven days and 14 days of α -mangostin preparation. In general, α -mangostin affects increasing bone volume.

Each α -mangostin concentration has different properties in inducing an increase in bone volume. The positive control (hyaluronic acid) has a different effect between 7 days with 14 days. Data represent means \pm SD (n=3). Based on the Kruskal-Wallis test analysis, there was no significant difference in changes in the volume of mandibular bone between α -mangostin concentrations ($p > 0.05$; 0.56), while based on the preparation time, there was no significant difference between day seven and day 14 ($p > 0.05$; 0.27). Time has an effect on changes in mandibular bone volume ($r = 0.48$) as well as concentration ($r = 0.23$).

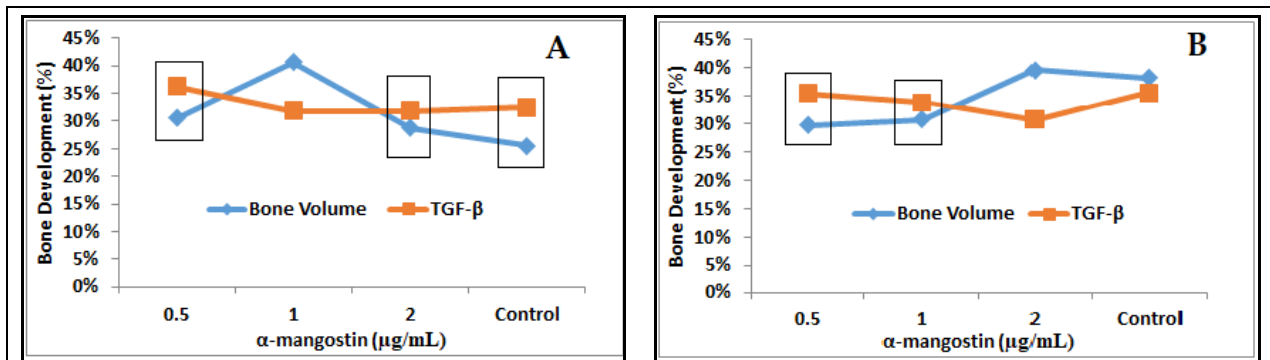


Figure 4. Bone volume and TGF- β 1 relation. A. 7 days and B. 14 days.

The α -mangostin has effect in bone volume after seven days (0.5% and 2%) and 14 days (0.5% and 1%). Meanwhile, the positive control (hyaluronic acid) maximizes seven days on bone development except in 14 days. They are related to the expression quantity of TGF- β 1. Data represent means \pm SD (n=3). Generally, α -mangostin affects increasing bone volume. Each α -mangostin concentration has different properties in inducing an increase in bone volume. Based on the One-Way ANOVA analysis, there was no significant difference in the α -mangostin concentration ($p > 0.05$; 0.85) with a positive correlation, meaning that the α -mangostin concentration was determined the development of volume and an increase of TGF- β 1 titer. Kruskal-Wallis test analysis showed no significant difference in bone volume development with an increase in TGF- β 1 ($p > 0.05$; 0.419) with a positive correlation and no significant time change factor ($p > 0.05$; 0.100).

DISCUSSION

This study's main objective was to report the effect of α -mangostin inducing the quantity of TGF- β 1 titer associated with increased bone volume in the mandibular bone in *Rattus norvegicus*, a model of periodontitis. TGF- β 1 is an inflammatory cytokine that is involved in bone remodeling and resorption by stimulating protein matrix synthesis. TGF- β signaling plays a role in regulating bone remodeling. During osteoclast bone resorption, TGF- β released from the bone matrix. The active TGF- β takes mesenchymal stem cells to the bone resorption hole via the SMAD signaling pathway (Crane et al., 2016). Structurally, SMAD is similar to the primary signal transducer for the TGF-beta superfamily receptor, regulating cell development and growth (Hata and Chen, 2016). This study

reported that α -mangostin and hyaluronic acid were similar in inducing increased bone volume and excretion of TGF- β 1 titer in mandibular bone. Chang et al. (2016) reported that hyaluronic acid effects could be increased osteoconduction and bone healing in clinical situations.

The α -mangostin induces a higher TGF- β 1 titer quantity at seven days than 14 days (Fig. 2). These results indicate that time correlates with the level of absorption and pharmacodynamic properties of the test material while in the area of infection. Ghiasi (2019) reported that within 7-14 days, bone forms loose cell aggregates interspersed with small blood vessels, known as granulation tissue. The osteoclasts move to reabsorb the bone's dead ends, and another necrotic tissue is removed (Ghiasi et al., 2019).

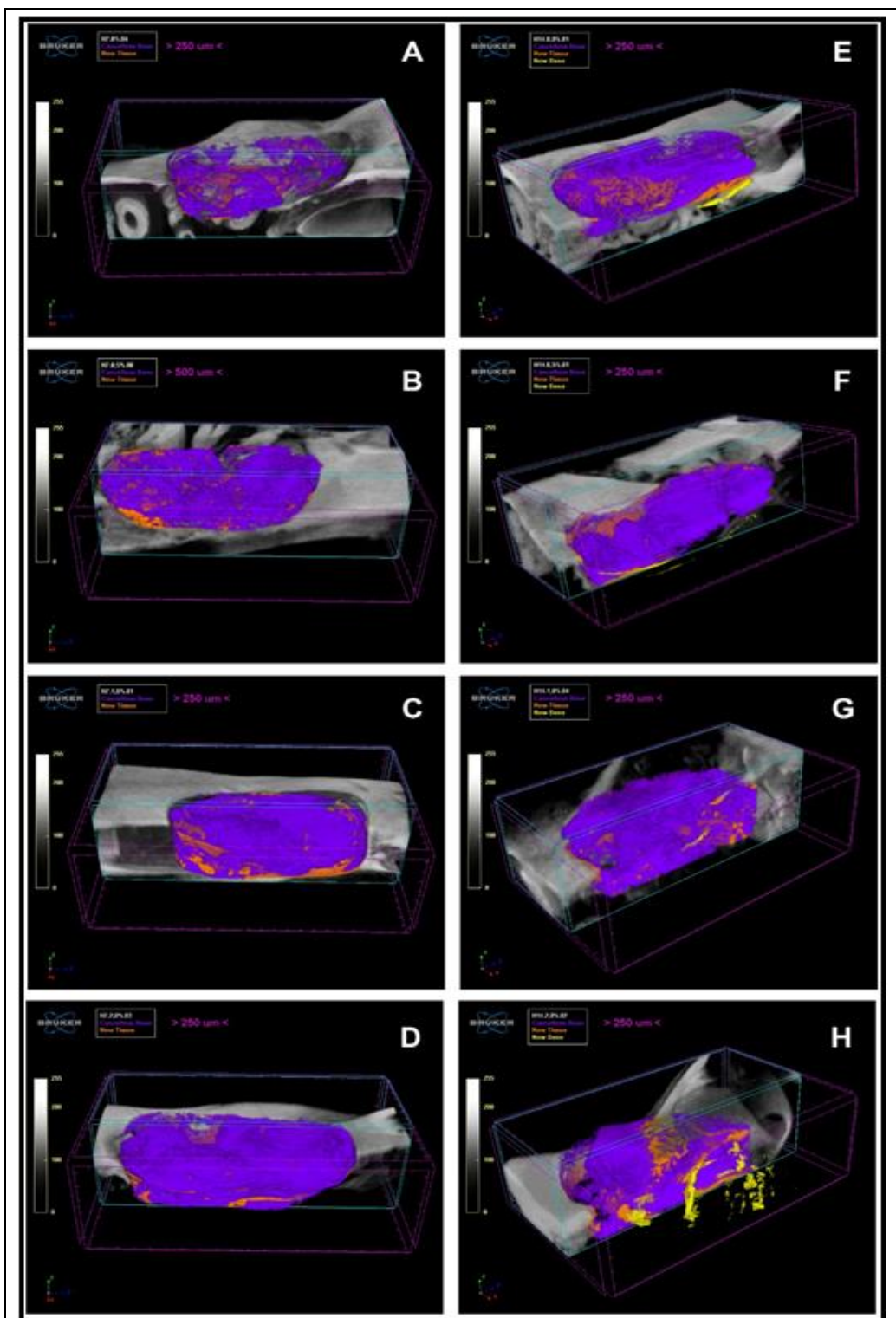


Figure 5. Micro-CT bone volume.

The control group (hyaluronic acid) (A) 7 days, (B) 14 days; α -mangostin group 0.5% (C) 7 days, (D) 14 days; α -mangostin 1%, (E) 7 days, (F) 14 days; and α -mangostin 2% (G) 7 days, (H) 14 days.

The control group of this study also showed signs of bone regeneration after trauma. However, α -mangostin can better affect increased bone volume as an indicator of new bone formation, mainly in concentration 2% at 14 days.

The increase in TGF- β 1 titer at seven days was related to the host immune system's inflammatory response activity during infection. The presence of blood and tissue antibodies has helped to accelerate the bone healing response. TGF- β 1, as an anti-inflammatory cytokine, works to provide a signal for the reaction to osteoblast formation (Baht et al., 2018). The TGF- β superfamily like TGF- β 2, - β 3, and GDF-5 have a role in endochondral chondrogenesis and ossification (Thielen et al., 2019). These cytokines initiate callus tissue formation that depends on the recruitment of mesenchymal stem cells from the soft tissue, cortex, periosteum, and bone marrow. Also, the systemic mobilization of stem cells into the peripheral blood from the hematopoietic site (Bonig and Papayannopoulou, 2012). Furthermore, bone healing and repair activity involves collagen-I and collagen-II matrices production (Marsell and Einhorn, 2011). This TGF- β signal's involvement has led to bone dimension changes as an indicator of repair and increased bone volume.

In line with pharmacological principles, the use of drugs for bone healing therapy must have the properties of recruiting and stimulating local or regional endogenous cells to differentiate into osteoblasts in the bone remodeling process. Also, it has properties to increase the host's immune system to reduce inflammation (Amini et al., 2012). Based on this theory concept, α -mangostin may have bone repair properties that meet pharmacological standards for achieving bone healing characterized by an increase in TGF- β 1 and accompanied by an increase in bone volume (Tarantino et al., 2009).

The data in Fig. 3 reported that α -mangostin affected increasing bone volume. Each α -mangostin concentration has different properties in inducing an increase in bone volume. It means that concentration determines bone development and response to healing through the bone metabolic healing mechanism. The repair and increase in bone volume are primarily determined by bone proteins' response, such as TGF- β 1, which guides the muscle cell defense system for bone healing (Loi et al., 2016). Besides, Micro-CT images of bone healing in this study showed the formation of new

callus or bone at the lesion's edges (Fig. 5). Several studies have compared bone density measurements using CT and have yielded histologically valid and representative results for bone structural parameters (Donnelly, 2011). This phenomenon is related to the function of TGF- β 1, which acts synergistically with TGF- α in promoting cell differentiation, hormone secretion, and immune function (Xu et al., 2018).

The increase in bone volume corresponds to the new bone formation that begins with osteoid deposition (Ott, 2008). Furthermore, anti-inflammatory cytokine prompts provide a signal to the defense system to carry out a corrective response. TGF- β has many effects on bone cells, depending on their phenotype and stage of differentiation. The TGF- β controls the production of osteoblasts or cells responsible for forming new bone through the differentiation or proliferation of osteoblasts (Bonewald and Mundy, 1990).

Furthermore, the linearity of the expression of the TGF- β 1 titer with the increase in mandibular bone volume after physical trauma as a model of periodontitis (Fig. 4) shows that α -mangostin can balance the host response to post-trauma new bone formation. Therefore, assumed that TGF- β 1 could inhibit the formation of osteoclast precursors and bone resorption in a greater concentration. Other studies have shown that TGF- β 1 can inhibit osteoclasts associated with bone resorption and bone formation (Weivoda et al., 2016). Osteoclasts have a role in bone degradation to initiate bone remodeling and mediate bone loss in pathological conditions by increasing their resorption activity (Boyce et al., 2009).

Bone remodeling is a bone resorption process that supplies calcium, phosphorus, carbonate, and bicarbonate salts to the extracellular media through the bone synthesis pathway to maintain the total bone mass (Florencio-Silva et al., 2015). The α -mangostin compound was shown to have an inducing effect of TGF- β 1, accompanied by an increase in mandibular bone volume in the periodontitis model. It was given a response to the rise in calcification and phosphorylation of mandibular bones. These two metal elements are a prerequisite

for bone growth or development. At least this assumption can be used as a new research concept to strengthen the role of α -mangostin in the mandibular bone remodeling process to obtain complete scientific information.

CONCLUSIONS

The α -mangostin compound with a single administration can increase the TGF- β 1 titer accompanied by increased bone volume. Based on the concentration and time of exposure, α -mangostin influences the quantity of TGF- β 1 titer involved in the mandibular bone remodeling process in the periodontitis model.

CONFLICT OF INTEREST

The authors declare no conflicts of interests.

ACKNOWLEDGMENTS

Thanks to Dr. Basri A. Gani, DVM, M.Sc., helped analyze the relationship between the quantity of TGF- β 1 titer and the increase in mandibular bone volume.

REFERENCES

- Amini AR, Laurencin CT, Nukavarapu SP (2012) Bone tissue engineering: recent advances and challenges. *Crit Rev Biomed Eng* 40: 363–408.
- Baht GS, Vi L, Alman BA (2018) The role of the immune cells in fracture healing. *Curr Osteoporos Rep* 16: 138–145.
- Bonewald LF, Mundy GR (1990) Role of transforming growth factor-beta in bone remodeling. *Clin Orthop Relat Res* 250: 261–276.
- Bonig H, Papayannopoulou T (2012) Mobilization of hematopoietic stem/progenitor cells: general principles and molecular mechanisms. *Methods Mol Biol* 904: 1–14.
- Boyce BF, Yao Z, Xing L (2009) Osteoclasts have multiple roles in bone in addition to bone resorption. *Crit Rev Eukaryot Gene Expr* 19: 171–180.
- Burhan E, Abidin T, Putra DP, Gani BA (2018) Analysis reactivity of *Punica granatum* polyphenols to the osteocalcin, bone morphogenetic protein-2, and collagen type-1. *Asian J Pharm Clin Res* 11(12): 544–547.
- Chang Y L, Lo YJ, Feng SW, Huang YC, Tsai, HY, Lin, CT, Fan KH, Huang, HM (2016) Bone healing improvements using hyaluronic acid and hydroxyapatite/beta-tricalcium phosphate in combination: an animal study. *BioMed Res Int* 2016: 8301624.
- Crane JL, Xian L, Cao X (2016) Role of TGF- β signaling in coupling bone remodeling. *Methods Mol Biol* 1344: 287–300.
- Donnelly E (2011) Methods for assessing bone quality: a review. *Clin Orthop Relat Res* 469: 2128–2138.
- du Plessis A, Broeckhoven C, Guelpa A, le Roux SG (2017) Laboratory x-ray micro-computed tomography: a user guideline for biological samples. *Gigascience* 6(6): 1–11.
- Florencio-Silva R, Sasso GRdS, Sasso-Cerri E, Simões MJ, Cerri PS (2015) Biology of bone tissue: structure, function, and factors that influence bone cells. *BioMed Res Int* 2015: 421746.
- Ghasemzadeh A, Jaafar HZ, Baghdadi A, Tayebi-Meigooni A (2018) Alpha-mangostin-rich extracts from mangosteen pericarp: optimization of green extraction protocol and evaluation of biological activity. *Molecules* 23(8): 1852.
- Ghiasi MS, Chen JE, Rodriguez EK, Vaziri A, Nazarian A (2019) Computational modeling of human bone fracture healing affected by different conditions of initial healing stage. *BMC Musculoskelet Disord* 20: 562.
- Gürkan A, Emingil G, Çınarcık S, Berdeli A (2006) Gingival crevicular fluid transforming growth factor- β 1 in several forms of periodontal disease. *Arch Oral Biol* 51: 906–912.
- Hajishengallis G (2015) Periodontitis: from microbial immune subversion to systemic inflammation. *Nat Rev Immunol* 15: 30–44.
- Hata A, Chen Y-G (2016) TGF- β signaling from receptors to Smads. *Cold Spring Harb Perspect Biol* 8: a022061.
- Hienz SA, Paliwal S, Ivanovski S (2015) Mechanisms of bone resorption in periodontitis. *J Immunol Res* 2015: 615486.
- Hong R-H, Liang Y-M, Pan H-S, Cheng Z-H, Li Y-H (2018) Alpha-mangostin suppresses receptor activator nuclear factor- κ B ligand-induced osteoclast formation and bone resorption in RAW264.7 cells by inhibiting the extracellular signal-regulated kinase and c-Jun N-terminal kinase signaling. *Pharmacog Mag* 14: 390.
- Hu K, Olsen BR (2016) The roles of vascular endothelial growth factor in bone repair and regeneration. *Bone* 91: 30–38.
- Jati AS, Furquim LZ, Consolaro A (2016) Gingival recession: its causes and types, and the importance of orthodontic treatment. *Dental Press J Orthod* 21: 18–29.
- Jiang N, Guo W, Chen M, Zheng Y, Zhou J, Kim SG, Embree MC, Songhee Song K, Marao HF, Mao JJ (2016) Periodontal ligament and alveolar bone in health and adaptation: tooth movement. *Front Oral Biol* 18: 1–8.
- Kantarci A, Tognoni CM, Yaghmoor W, Marghalani A, Stephens D, Ahn J-Y, Carreras I, Dedeoglu A (2020) Microglial response to experimental periodontitis in a murine model of Alzheimer's disease. *Sci Rep* 10(1): 18561.
- Kasagi S, Chen W (2013) TGF-beta1 on osteoimmunology and the bone component cells. *Cell Biosci* 3(1): 4.

- Kilkenny C, Browne W, Cuthill IC, Emerson M, Altman DG (2010) Animal research: reporting *in vivo* experiments: the ARRIVE guidelines. *Br J Pharmacol* 160(7): 1577–1579.
- Könönen E, Gursoy M, Gursoy UK (2019) Periodontitis: a multifaceted disease of tooth-supporting tissues. *J Clin Med* 8: 1135.
- Kresnoadi U, Ariani MD, Djulaeha E and Hendrijantini N (2017) The potential of mangosteen (*Garcinia mangostana*) peel extract, combined with demineralized freeze-dried bovine bone xenograft, to reduce ridge resorption and alveolar bone regeneration in preserving the tooth extraction socket. *J Indian Prosthodont Soc* 17: 282–288.
- Loi F, Córdova LA, Pajarinen J, Lin T-H, Yao Z, Goodman SB (2016) Inflammation, fracture and bone repair. *Bone* 86: 119–130.
- Marsell R, Einhorn TA (2011) The biology of fracture healing. *Injury* 42: 551–555.
- Mahato N, Sinha M, Sharma K, Koteswararao R, Cho MH. (2019) Modern extraction and purification techniques for obtaining high purity food-grade bioactive compounds and value-added co-products from citrus wastes. *Foods* 8(11): 523.
- Nam MH, Chun MS, Seong JK, Kim HG (2018) Ensuring reproducibility and ethics in animal experiments reporting in Korea using the ARRIVE guideline. *Lab Anim Res* 34(1): 11–19.
- Ng'uni T, Klaasen JA, Fielding BC (2018) Acute toxicity studies of the South African medicinal plant *Galenia africana*. *Toxicol Rep* 5: 813–818.
- Ott SM (2008) Histomorphometric measurements of bone turnover, mineralization, and volume. *Clin J Am Soc Nephrol Suppl* 3: S151–S156.
- Schätzle M (2005) The role of gingivitis in the loss of periodontal attachment and teeth. Dissertation. Department of Periodontology, Faculty of Odontology, Malmö University, Sweden, pp. 9-78
- Soares PBF, Fernandes Neto AJ, Magalhães D, Versluis A, Soares CJ (2011) Effect of bone loss simulation and periodontal splinting on bone strain: periodontal splints and bone strain. *Arch Oral Biol* 56: 1373–1381.
- Song M (2019) Dental care for patients taking antiresorptive drugs: a literature review. *Restor Dent Endod* 44: e42.
- Tarantino U, Cerocchi I, Celi M, Scialdoni A, Saturnino L, Gasbarra E (2009) Pharmacological agents and bone healing. *Clin Cases Miner Bone Metab* 6: 144–148.
- Thielen NGM, van der Kraan PM, van Caam APM (2019) TGF β /BMP signaling pathway in cartilage homeostasis. *Cells* 8: 969.
- Wactawski-Wende J, Grossi SG, Trevisan M, Genco RJ, Tezal M, Dunford RG, Ho AW, Hausmann E, Hreshchysyn MM (1996) The role of osteopenia in oral bone loss and periodontal disease. *J Periodontol* 67: 1076–1084.
- Weivoda MM, Ruan M, Pederson L, Hachfeld C, Davey RA, Zajac JD, Westendorf JJ, Khosla S, Oursler MJ (2016) Osteoclast TGF- β receptor signaling induces Wnt1 secretion and couples bone resorption to bone formation. *J Bone Miner Res* 31: 76–85.
- Xu X, Zheng L, Yuan Q, Zhen G, Crane JL, Zhou X, Cao X (2018) Transforming growth factor- β in stem cells and tissue homeostasis. *Bone Res* 6: 2.
- Yang Z, Han L, Guo Y, Jia L, Yin C, Xia Y (2020) Nanotechnology in Dental Therapy and Oral Tissue Regeneration. In *Nanotechnology in Regenerative Medicine and Drug Delivery Therapy*, Springer, pp. 91–189.

AUTHOR CONTRIBUTION:

Contribution	Lestari C	Darwin E	Putra DE	Suharti N
Concepts or ideas	x	x	x	x
Design	x	x	x	
Definition of intellectual content		x	x	
Literature search	x			x
Experimental studies	x	x	x	x
Data acquisition	x			
Data analysis	x	x	x	
Statistical analysis		x	x	
Manuscript preparation	x	x	x	
Manuscript editing	x	x	x	x
Manuscript review	x	x	x	x

Citation Format: Lestari C, Darwin E, Putra DE, Suharti N (2021) The α -mangostin effect on the quantity of TGF- β 1 titer relate to the mandibular bone volume of *Rattus novergicus* in the periodontitis model. *J Pharm Pharmacogn Res* 9(5): 609–618.