

The Effect of Cigarette Smoke Exposure on Histology Liver in Male Mice

by Dessy Abdullah

Submission date: 27-May-2022 04:13PM (UTC+0800)

Submission ID: 1845210818

File name: ect_ofCigarette_Smoke_Exposure_onHistology_Liver_inMale_Mice.pdf (277.11K)

Word count: 3180

Character count: 16182

Research Article,

The Effect of Cigarette Smoke Exposure on Histology Liver in Male Mice

Meta Zulyati Oktora¹, Dessy Abdullah², Tazkiya Nur Annisa³

¹Department of Pathology Anatom³, Faculty of Medicine, Baiturrahmah University, Padang, Indonesia

²Department of Pharmacology, Faculty of Medicine, Baiturrahmah University, Padang, Indonesia

³Student, Faculty of Medicine, Baiturrahmah University, Padang, Indonesia Department

Email Address: metazulyantioktora@fk.unbrah.ac.id

Abstract:

When smoking Reactive Oxygen Species (ROS), which is a reactive oxidizing agent, can cause damage to the DNA structure of liver cells and increase the occurrence of liver necrosis. The research aims to determine the histopathological picture of the liver in male mice (*Mus musculus*) exposed to cigarette smoke. This research is an experimental laboratory with the sample used is male mice (*Mus musculus*). The sample with the most damage in treatment I obtained 5 (55.6%) samples with a score of 2 who had damage to hepatocytes. , 7 (77.8%) samples with a score of 3 had central venous dilation, 3 (33.3%) samples with a score of 1 had fatty liver, and 3 (33.3%) samples with a score of 1 had liver necrosis. While in treatment II, 5 (55.6%) samples with a score of 2 had hepatocyte cell damage, 8 (88.9%) samples with a score of 3 had central vein dilation, 5 (55.6%) samples with a score of 3 had fatty liver, and 5 (55.6%) samples with a score of 2 had liver necrosis. Based on these results, the histopathological changes in the liver of male mice (*Mus musculus*) were exposed to cigarette smoke.

Keywords: Cigarette Smoke, Histopathology, Liver, Male Mice (*Mus musculus*).

Introduction:

Cigarettes have become an endless phenomenon even though the World Health Organization (WHO) has warned about the dangers of cigarettes and is the most dangerous killer, but with warnings in fact there are still many consumers who continue to grow and cigarette production continues to spread throughout the world.(1) Cigarettes contain many substances that are harmful to the body, tobacco contains 2.500 known chemicals and 4.800 chemical substances in cigarette smoke that can threaten and endanger human health, including NO, tar, nicotine, and CO gas. present in tobacco and other materials such as pesticides, fertilizer residue, NTRM (nontobacco related material), TSNA (tobacco-specific nitrosamine), and Bap (benzo-a-pyrene) which are present during the processing, planting, and presentation in trade. The content that can cause

disruption of oxygen exchange in the body so that smokers become easily tired is carbon monoxide, this substance will be and settle in the lungs, causing lung work to decrease then nicotine content can cause dependence and addiction to cigarettes.(2)

If cigarettes are consumed for a long period of time, it will cause several diseases including : heart disease, impotence, reproductive and erectile disorders, stomach ulcers, chronic respiratory disorders, stroke, burger disease, osteoporosis, hair loss, premature aging, damage to organs of vision and hearing loss, tooth decay, various types of cancer, and the most fatal can cause death.(3) Based on BPJS 2018 data, there are 12 types of cancer-related to smoking, namely cancer of the pancreas, kidneys, bladder, mouth, pharynx, larynx, esophagus, liver, stomach, lung, leukemia, and cervix.(4)

The liver is the largest organ after skin and the heaviest gland in humans with a weight of 1500 grams, equivalent to 2.5% of an adult's body weight. The liver fills almost all of the right hypochondrium and epigastrum, the location of the liver extends into the left hypochondrium next to the inferior diaphragm to separate the lungs, pleura, perichondrium, and heart.(5) This organ is important for the body as a detoxifier of toxins that are no longer needed by the body, this process works with the help of one of the enzymes, namely the glucuronyltransferase enzyme, besides that the liver also produces catalase enzymes which are useful for the body to ward off free radicals. If there are fewer antioxidants in the liver cells than the free radicals in the body, over time the liver cells will degenerate, resulting in liver necrosis. Smoking is a risk factor that can cause damage to the shape of liver cells. When smoking Reactive Oxygen Species (ROS), which is a reactive oxidizing agent produced by cigarettes, will increase and can cause damage to the DNA structure of liver cells and can increase the occurrence of liver necrosis and oxidative stress.(6) Oxidative stress describes an imbalance between antioxidant and oxidant produced in the body, so it can cause damage, especially damage to cells in the body. Under conditions of oxidative stress, there is nitric oxide (NO) which forms oxidized molecules with one of the ROS, namely Superoxide anion, to Peroxynitrite which can cause changes in gene transcription, protein formation, and trigger DNA damage.(7)

The most dangerous substance in cigarettes is nicotine, the nicotine content that comes from cigarettes that have been inhaled will pass through the lungs and later by the blood will be carried to the liver because the liver is an organ that can metabolize nicotine. The result of nicotine metabolism is the metabolite compound N-nitrosamine in the form of 4-(methyl-nitrosamine)-1-(3-pyridyl)-1-butanone (NNK), this metabolite is a strong carcinogenic compound found in the liver that can affect liver damage. and interfere with the metabolic function of the liver.(8) Continuous exposure to cigarette smoke will cause a toxic effect that is getting bigger and slowly causes liver damage such as hepatocyte necrosis with a microscopic appearance, namely cells that have dead, dense, and smaller nuclei with chromatin and reticular fibers that are folded. The cells can become eosinophilic or cariolytic,

the toxic effects of smoking can also cause disruption of liver function.(9)

Methods:

This research was carried out at the Pharmacology Laboratory of Andalas Padang University, the Anatomical Pathology Laboratory of the Siti Rahmah Islamic Hospital, and the Laboratory of the Faculty of Medicine, Baiturrahmah University, Padang from August to December 2021. The sample of this study was male mice (*Mus musculus*) aged 25-30 weeks, with a bodyweight of 25-30 grams. The number of mice (*Mus musculus*) was 27 grouped into 3 groups, namely the negative control group (KN), treatment group I (KP I), and treatment group II (KP II) where each group consisted of 9 male mice.

This type of research is descriptive categorical with laboratory experimental methods. The treatment group I was the group that was given exposure to cigarette smoke for 14 days, treatment group II was for 28 days, and the negative non-control group was the group that was not exposed to cigarette smoke. Liver organs were taken and made preparations with hematoxylin-eosin staining to check for damage to the liver. Cigarette smoke exposure was carried out in a wire cage covered with plastic with a size of 40 x 40 x 35 and with holes at the top and bottom exposed as many as 3 cigarettes per day for 30 minutes.

Results:

This study used 9 mice in each treatment group based on the inclusion criteria, from the results of data collection and analysis obtained:

Table1. Frequency distribution of samples of liver histopathology in mice (*mus musculus*) by observing the presence of hepatocyte cell damage

Damage Score	f	%
Score 0	0	0
Score 1	3	33,3
Score 2	5	55,6
Score 3	1	11,1
Total	9	100

Treatment Group I

2 Damage Score	f	%
Score 0	0	0
Score 1	0	0
Score 2	5	55,6
Score 3	4	44,4
Total	9	100

Treatment Group II

Based on table 3, it was found that in the treatment group I out of 9 samples there were 3 samples (33.3%) most of which were included in the score 1, namely there was fatty liver < 1/3 of the entire field of view. Meanwhile, in the second treatment group, there were 5 samples (55.6%) with a score of 3, which was fatty liver >2/3 of the entire field of view.

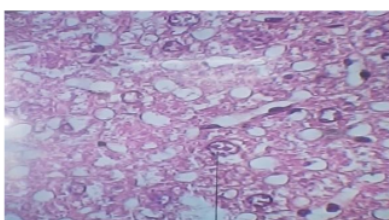


Figure1. Hepatocyte cells cariorexic

Table2. Frequency distribution of samples of liver histopathology in mice (mus musculus) by observing the presence of dilation of the central vein

2 Damage Score	f	%
Score 0	0	0
Score 1	1	11,1
Score 2	1	11,1
Score 3	7	77,8
Total	9	100

Treatment Group I

Treatment Group II

Based on table 2, it was found that in treatment group I out of 9 samples there were 7 samples (77.8%) most of which were included in the score 3. While in treatment group II there were 8 samples (88.9%) the most with a score of 3, namely dilation of the central vein. >2/3 of the total field of view.

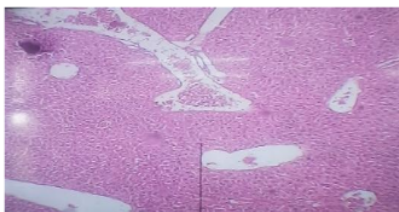


Figure2. Dilatation of central vein

Table3. Frequency distribution of samples of liver histopathology in mice (mus musculus) by observing the presence of fatty liver

Damage Score	f	%12
Score 0	4	44,4
Score 1	3	33,3
Score 2	2	22,2
Score 3	0	0
Total	9	100

Treatment Group I

3 Damage Score	f	%
Score 0	0	0
Score 1	3	33,3
Score 2	1	11,1
Score 3	5	55,6
Total	9	100

Treatment Group II

Based on table 3, it was found that in the treatment group I out of 9 samples there were 3 samples (33.3%) most of which were included in the score 1, namely there was fatty liver < 1/3 of the entire field of view. Meanwhile, in the second treatment group, there were 5 samples (55.6%) with a score of 3, which was fatty liver >2/3 of the entire field of view.

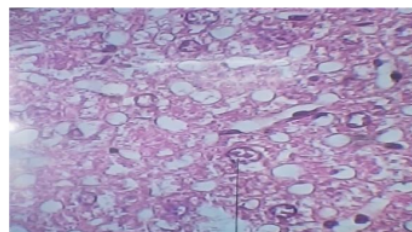


Figure3. Fatty Liver

Table4. Frequency distribution of samples of liver histopathology in mice (mus musculus) by observing the presence of liver necrosis

Damage Score	f	%
Score 0	6	66,7
Score 1	3	33,3
Score 2	0	0
Score 3	0	0
Total	9	100

Treatment Group I

2 Damage Score	f	%
Score 0	0	0
Score 1	0	0
Score 2	1	11,1
Score 3	8	88,9
Total	9	100

Treatment Group II

Based on table 4, it was found that in the treatment group I out of 9 samples there were 3 samples (33.3%) most of which were included in the score 1, namely there was liver necrosis <1/3 of the entire field of view. Meanwhile, in the second treatment group, there were 5 samples (55.6%) with a score of 2, which was experiencing hepatic necrosis 1/3-2/3 of the entire field of view.

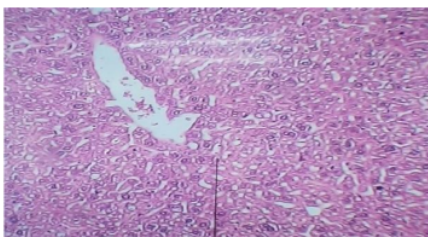


Figure4. Necrosis Liver

Discussion:

1. Histopathological description of the liver in mice (*Mus musculus*) by observing the presence of hepatocyte cell damage

Caryorexic cells have irreversible properties because there is damage to the plasma membrane, lysosomes, cell membrane dysfunction, mitochondrial dysfunction, and loss of DNA. The picture seen in cariorexic cells is that there is a fragmented cell nucleus. (10) The occurrence of hepatocyte cell damage due to cigarette smoke can affect the metabolic work of macrophages which release leukotrienes TNF- α , B4, and IL-8 and in turn, can increase the production of superoxide and H₂O₂ and form free radicals that cause oxidative stress in the liver and trigger lipid peroxidation in the liver. Cell membranes can eventually cause damage to hepatocytes. Liver cell damage can trigger excessive cell proliferation so that in the long term it will cause liver cancer or tumor formation.(11)

2. Histopathological description of the liver in mice (*Mus musculus*) by observing the presence of dilation of the central vein

Free radicals contained in cigarettes can increase fat peroxidation and cause sinusoid damage which results in pressure on the sinusoid walls due to dams in the veins in the form of blood accumulation caused by toxic substances contained in cigarettes. The blood flow to the liver will flow through the sinusoids and into the central vein.(12) Blood will carry metabolic products from hepatocytes including metabolic products that are toxic, the central vein will accumulate metabolic products and the number of toxic substances contained in the blood can cause lysis of central venous endothelial cells. This lysis process causes an increase in the diameter of the central vein.(13)

3. Histopathological description of the liver in mice (*Mus musculus*) by observing the presence of fatty liver

The process of the fatty liver occurs due to the presence of ROS, one of which is found in cigarettes, causing an imbalance between the breakdown and formation of triglycerides eventually causing an increase in triglyceride transport and an increase in lipolysis, especially in adipose in the middle of the body, which then results from lipolysis will be carried through the portal vein. to the liver for processing and causes increased levels of fat in the liver.(14) High levels of fat in the liver will cause adipose accumulation in hepatocyte cell(14) and can potentially lead to liver cirrhosis and non-alcoholic fatty liver disease.(15)

Fat levels in the blood will increase within 2 hours after smoking in the amount of 2-5 sticks.(16) Fatty liver in humans is reversible (recoverable) supported by a healthy lifestyle. Factors that can cause NAFLD are obesity, insulin resistance usually in type 2 DM patients, and high cholesterol levels.(17) Chemical substances contained in cigarettes can increase levels of Low Density Lipoprotein (LDL) cholesterol and reduce levels of High Density Lipoprotein (HDL) cholesterol. People who smoke are found to have low HDL levels, which means that the formation of HDL, which carries fat from the tissues to the liver, is disrupted as opposed to LDL. Smokers have high LDL levels, which means the fat from

the liver will be brought back to the body's tissues.(18)

4. Liver Histopathology in Mice (*Mus musculus*) by Observing Liver Necrosis

Liver necrosis results in swelling of the mitochondria and cytoplasm, which can lead to rupture of the plasma membrane.(19) When the plasma membrane ruptures, it will result in an increase in sodium ion levels in the cell, thereby inhibiting the work of ATPase which functions for the integrity of liver cells, regulating the transport of sodium and potassium. fragmentation of DNA and chromatin. If the level of ATP is low, it will cause damage to liver cells and if it is severe, over time it will cause necrosis of the liver.(20)

Conclusion:

Based on the results of research that has been carried out, there are histological changes in the liver of male mice that have been exposed to cigarette smoke with the frequency of damage scores.

Acknowledgments

The author expresses their deepest gratitude to the Head of the Pharmacology Laboratory of the Faculty of Pharmacy, the Anatomical Pathology Laboratory of the Siti Rahmah Islamic Hospital, Padang, and the Laboratory of the Faculty of Medicine, Baiturrahmah University, Padang. To provide all meaningful encouragement and support in completing the entire research

References:

[1] Khoirunnisa A, P PN, Cahyo K. Beberapa Faktor yang Mempengaruhi Praktik Merokok Santri Di Pondok Pesantren Darut Taqwa Kota Semarang. *Jurnal Kesehatan Masyarakat*. 2019;7(1):430–41.

[2] Sari MJ, Yanto Y, Sari S. Sikap Perokok Aktif Dalam Menanggapi Peringatan Bahaya Merokok Pada Iklan Rokok Di Televisi (Studi Masyarakat Desa Talang Jambu Kecamatan Kerkap Kabupaten Bengkulu Utara). *Prof J Komun dan Adm Publik*. 2019;6(1):81–9.

[3] Hamdan SR. Pengaruh Peringatan Bahaya Rokok Bergambar Pada Intensi Berhenti Merokok. *MIMBAR, J Sos dan Pembang*. 2015;31(1):241.

[4] Puspawati PR, Kristina SA, Wiedyaningsih C. Dampak Merokok Terhadap Kematian Dini Akibat Kanker di Indonesia: Estimasi

Years of Life Lost (YLL). *Maj Farm*. 2020;16(1):101–6.

[5] Neza UHS, Widya PM, Tarrinni I, Rizki Hanriko. Pengaruh Pemberian Kombinasi Zinc dan Tomat (*Solanum Lycopersicum L*) terhadap Hepar Akibat Stres yang Terpapar Gelombang Elektromagnetik Ponsel. *J Agromedicine*. 2019;6(2):325–31.

[6] Akbar MY. Pengaruh Madu Terhadap Hepar Mencit yang Terpapar Asap. *J Ilm Kesehat Sandi Husada*. 2020;12(2):1017–22.

[7] Norazizah S, Wibisono N, Wahyuningsih D. Systematic Literature Review : Pomegranate Improves Nitric Oxide Level In Oxidative Faculty of Medicine University Of Islam Malang. 2020.

[8] Nadia L. Pengaruh Negatif Merokok terhadap Kesehatan dan Kesadaran Masyarakat Urban. Pengaruh Negatif Merokok terhadap Kesehatan dan Kesadaran Masyarakat Urban [Internet]. 2016;28(02):77–104.

[9] Prasetiawan E, Sabri E, Ilyas S. Gambaran Histologis Hepar Mencit (*Mus Musculus L.*) Strain Ddw Setelah Pemberian Ekstrak N-Heksan Buah Andaliman(*Zanthoxylum Acanthopodium Dc.*) Selama Masa Pra Implantasi Dan Pasca Implantasi. *Saintia Biol*. 2012;1(1):40–5.

[10] Maulina M. Zat-Zat yang Mempengaruhi Histopatologi Hepar. *Unimal Press*. 2018;49:1.

[11] Agata A, Widiastuti EL, Susanto GN, ' S. Respon Histopatologis Hepar Mencit (*Mus musculus*) yang Diinduksi Benzo(α)Piren terhadap Pemberian Taurin dan Ekstrak Daun Sirsak (*Annona muricata*). *J Natur Indones*. 2017;16(2):54.

[12] Ari Hepi Yanti RPPDWR. Aktivitas Hepatoprotektif Ekstrak Metanol Buah Lakum (*Cayratia trifolia (L.) Domin*) Terhadap Diameter Vena Sentralis, Lebar Sinusoid dan Berat Hepar Tikus Putih (*Rattus novergicus L.*) yang Diinduksi Parasetamol. *J Protobiont*. 2018;7(3):72–6.

[13] Wicaksono.HS, Narayani.I S. Struktur Hati Mencit (*Mus Musculus L*) Setelah Pemberian Ekstrak Daun Kaliandra Merah. *J Biol FMIPA Univ Udayana*. 2015;I:258–68.

[14] Dyson.JK, Anstee.QM MS. Non Alcoholic Fatty Liver Disease : A Practical Approach to Treatment. *Frontline Gastroenterol*. 2014;1–10.

- [15] Jurnal YD, Sayoeti Y, Elfitrimelly E. Peran Antioksidan pada Non Alcoholic Fatty Liver Disease (NAFLD). *J Kesehat Andalas*. 2014;3(1):15–20.
- [16] Nisa H, Artha DE, Risma. Pengaruh Rokok Terhadap Kadar Kolesterol 2 Jam Setelah Merokok Pada Perokok Aktif. *J Media Laboran*. 2018;8(1):33–8.
- [17] Dewi E, Fadliyani, Ismiranda. Efek Diet Aterogenik Terhadap Gambaran Histopatologis Hati Mencit (*Mus musculus*). 2016;VIII:31–6.
- [18] Surasa N, Utami N, Isnaeni W. Struktur Mikroanatomi Hati dan Kadar Kolesterol Total Plasma Darah Tikus Putih Strain Wistar Pasca Suplementasi Minyak Lemuru dan Minyak Sawit. *Biosaintifika J Biol Biol Educ*. 2014;6(2):117–27.
- [19] Saputra D, Astuti ER, I. BT. Apoptosis Dan Nekrosis Sel Mukosa Rongga Mulut Akibat Radiasi Sinar-x Dental Radiografik Konvensional. *Radiol Dent J*. 2012;3(1):36–40.

The Effect of Cigarette Smoke Exposure on Histology Liver in Male Mice

ORIGINALITY REPORT

11 %
SIMILARITY INDEX

9 %
INTERNET SOURCES

8 %
PUBLICATIONS

%
STUDENT PAPERS

PRIMARY SOURCES

1 valleyinternational.net **2** %
Internet Source

2 pt.scribd.com **1** %
Internet Source

3 www.ijss-sn.com **1** %
Internet Source

4 Edrizal Edrizal, Eka Desnita. "PENGARUH CANGKANG KEONG SAWAH (PILA AMPULLACEA) TERHADAP PEMBENTUKAN TULANG BARU (REMODELING TULANG)", Health & Medical Journal, 2020 **1** %
Publication

5 core.ac.uk **1** %
Internet Source

6 www.scilit.net **1** %
Internet Source

7 docplayer.net **1** %
Internet Source

8	en.wikipedia.org Internet Source	<1 %
9	link.springer.com Internet Source	<1 %
10	repository.uin-malang.ac.id Internet Source	<1 %
11	<p>E L Widiastuti, B K Ardiansyah, N Nurcahyani, A Silvinia. " Antidiabetic Potency of Jeruju (L.) Ethanol Extract and Taurine on Histopathological Response of Mice Kidney (L.) Induced by Alloxan ", Journal of Physics: Conference Series, 2021</p> Publication	<1 %
12	<p>Marga C. Ocké, H. Bas Bueno - de - Mesquita, Edith J.M. Feskens, Daan Kromhout, Alessandro Menotti, Henry Blackburn. "Adherence to the European code against cancer in relation to long - term cancer mortality: Intercohort comparisons from the seven countries study", Nutrition and Cancer, 1998</p> Publication	<1 %
13	ojs.unud.ac.id Internet Source	<1 %
14	www.wjgnet.com Internet Source	<1 %

15

Sholahuddin Rhatomy, Rizki Rahmadian, Faiz Alam Rasyid, Evlin Margaretha. "Adductor Canal Block in the Outpatient Clinic for Pain Control Following Knee Surgery",
Anesthesiology and Pain Medicine, 2021

Publication

<1 %

16

repository.wima.ac.id

Internet Source

<1 %

Exclude quotes On

Exclude matches < 3 words

Exclude bibliography On